

# ChEVAR technique for emergent aneurysm repair - a retrospective case series

Carlos Veterano<sup>a</sup> , Pedro Sá Pinto<sup>a,b</sup> , Carlos Pereira<sup>a,b</sup>, Joana Martins<sup>a,b</sup>, Daniel A. Mendes<sup>a</sup> , Henrique Rocha<sup>a</sup> ,  
Andreia Pinelo<sup>a</sup> , Rui Machado<sup>a,b,c</sup> 

<sup>a</sup> Angiology and Vascular Surgery Department, Centro Hospitalar Universitário de Santo António, Porto, Portugal. <sup>b</sup> Kidney Transplantation Unit, Centro Hospitalar Universitário de Santo António, Porto, Portugal. <sup>c</sup> Instituto Ciências Biomédicas Abel Salazar, Porto, Portugal

Submitted: May 15, 2023; Reviewed: June 10, 2023; Accepted: June 29, 2023.

Presented at: 22nd SPACV Annual Meeting, May 2023

## ABSTRACT

**INTRODUCTION:** Chimney EVAR (ChEVAR) for the treatment of complex abdominal aortic aneurysm (AAA) has been largely relegated for when fenestrated endografts are unavailable, especially due to durability concerns. However, the off-the-shelf nature of ChEVAR makes it a good option for emergent AAA repair. We report our institutional experience in ChEVAR in an urgent setting.

**METHODS:** ChEVAR procedures were collected from 2019 to 2023 in a tertiary hospital, and a retrospective analysis was performed. This includes gathered information from electronic medical records, surgical reports and the picture archiving system. Descriptive statistics were applied. The main endpoints were technical success, 30-day and 1-year survival.

**RESULTS:** Five patients were submitted to urgent aneurysm repair using the chEVAR technique. Average age was 73,4 years and all patients were male. Arterial hypertension was present in 100% patients and all patients were ASA 4. Indications for surgery were post EVAR type 1a endoleak with associated rupture or abdominal pain in two patients; symptomatic/contained rupture of pararenal AAA in two patients; and contained rupture of a thoracoabdominal aneurysm in one patient.

A total of eight target vessels were catheterized: two patients required single-vessel chimney and the remainder two-vessel chimney. Target vessels were two superior mesenteric arteries and six renal arteries. Technical success rate was 100% and 30-day mortality was 0%. There were no major complications. Follow-up time is 20.2 months (4.7-38). Target vessel patency during the follow-up period was 87.5%. Three patients (60%) died due to non-aortic related pathologies, on average 18 months after surgery (4.7-38), with a 1-year survival of 80%.

**CONCLUSION:** Our experience with ChEVAR for emergent AAA repair is satisfactory, with high technical success rates and low short-term mortality. Sac regression, low rates of target vessel occlusion and type 1a endoleaks reveal a favourable profile for aneurysm exclusion. ChEVAR is a viable option in emergent setting for patients unfit for open repair.

**Keywords:** Aortic Aneurysm, Abdominal; Aneurysm, Ruptured; Endovascular Aneurysm Repair; Chimney; Parallel stents.



## INTRODUCTION

Proximal juxtarenal involvement in aortic abdominal aneurysm (JAAA) may preclude the traditional endovascular aortic repair (EVAR). Recent endovascular techniques have been employed for those with neck lengths inferior to 10mm, such as fenestrated/branched EVAR (f/bEVAR) and parallel graft such as chimney EVAR (ChEVAR).<sup>[1]</sup> These techniques aim to achieve a durable proximal aortic neck while maintaining patency of visceral branches.

Parallel stentgraft techniques such as ChEVAR were initially used for “bail-out” in patients with inadequate landing zones and accidental visceral coverage.<sup>[2]</sup> Their current application for complex AAAs has been relegated for when there is unavailability of f/bEVAR endografts, especially due to durability concerns.<sup>[3]</sup> However, the off-the-shelf nature of the ChEVAR technique makes it a good alternative for urgent/emergent AAA repair. We report our institutional experience in ChEVAR in urgent setting.

## METHODS

### Cohort selection

This is a single-centre retrospective study of consecutive ChEVAR procedures collected from January 2019 to March 2023 in a tertiary hospital. Inclusion criteria were procedures for aneurysm repair (JAAA or TAAA) performed in urgent/emergent setting in which chimney technique was employed. ChEVAR performed in elective setting were excluded.

### Definitions

The Crawford classification was used for the extent of thoracoabdominal aneurysms. Sac regression was the reduction in maximum diameter of the aneurysm sac by  $\geq 5$  mm.

### Outcomes

Primary outcomes were technical success, 30-day mortality and 1-year mortality rates. Secondary outcomes were target vessel patency. Surveillance strategy consisted of Computed Tomography Angiography (CTA) performed during admission, 30 days, six months and yearly. Imaging collection and analysis was performed using the centre's workstation Sectra IDS7 (Sectra AB, Linköping, Sweden).

### Statistical analyses

Due to the small size of the cohort, only a descriptive statistical analysis was performed. Normally distributed data is presented as mean (interval). Collected data was analysed in SPSS statistical software, version 23.0 (SPSS Inc, Chicago, USA).

## RESULTS

### Demographics

We report a series of 5 patients (Figure) submitted to emergent/urgent aneurysm repair using ChEVAR technique. Average age was 73,4 years (45-89) and all patients were male. Arterial hypertension was present in 100% patients; 80% were former smokers and all patients were ASA 4 (American Society of Anesthesiologists). Indications for surgery were: post EVAR type 1a endoleak with associated rupture or symptomatic in two patients; symptomatic/contained rupture of JAAA in two patients; and contained rupture of a thoracoabdominal aneurysm (TAAA) in one patient. The latter, a 45-year-old male with a type 4 TAAA, was submitted to ChEVAR technique based on previous laparotomies and associated intra-abdominal infection.

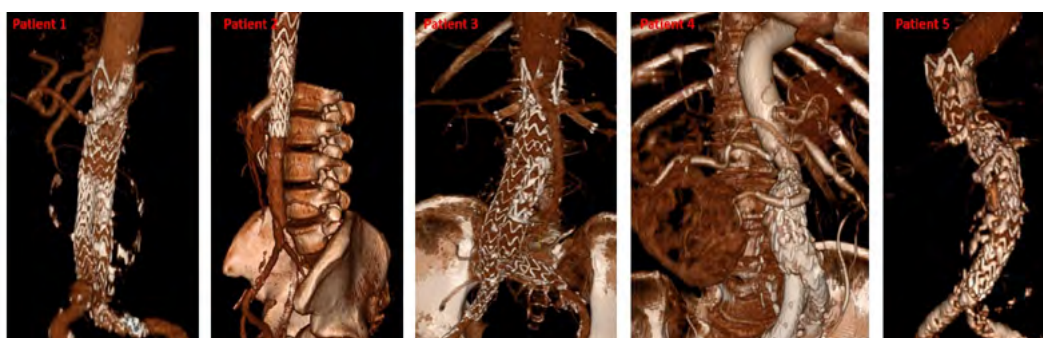
**Table 1.** Pre-operative characteristics of patients treated with ChEVAR for emergent aneurysms.

### Patient characteristics

Age, years (range)	73,4 (45-89)
Male gender – N	5/5
Cardiac insufficiency	3/5
Coronary artery disease	4/5
COPD	2/5
Pre-operative CKD	0/5
Dyslipidaemia	3/5
Active smoking	1/5
Hypertension	5/5
Previous aortic surgery	2/5
ASA score 4	5/5
Aneurysm type	
Type IV TAAA	1/5
Juxtarenal AAA	4/5
Proximal neck length, mm (range)	6,4 (4-10)

AAA abdominal aortic aneurysm; ASA American Society of Anesthesiologists; CKD chronic kidney disease; COPD chronic obstructive pulmonary disease; TAAA thoracoabdominal aortic aneurysm.

**Figure.** Postoperative computed tomography 3D reconstructions of patients treated with ChEVAR for acute abdominal aneurysm, included in this case-serie



**Table 2.** Operative details of patients treated with ChEVAR for emergent aneurysms

Patient	Aortic stent graft	Aneurysm characteristics	Stent graft diameter (mm)	Proximal fixation (Ishimaru zones)	Number of chimneys	Chimney configuration	Chimney stentgraft
1	Endurant (Medtronic)	Ruptured AAA with type 1a EL	36	8	1	LRA	Viabahn VBX (Gore)
2	TAG (Gore)	Ruptured TAAA4	31	5 (previous TEVAR)	2	RRA (periscope) and SMA (chimney)	Viabahn VBX (Gore)
3	Endurant (Medtronic)	Symptomatic JAAA	28	8	2	RRA and LRA	Viabahn VBX (Gore)
4	Excluder (Gore)	Ruptured AAA with type 1a EL	28,5	8	1	Single renal artery (horseshoe)	Viabahn VBX (Gore)
5	Endurant (Medtronic)	Ruptured JAAA	36	7	2	RRA and SMA	Viabahn VBX (Gore)

**AAA** abdominal aortic aneurysm; **JAAA** juxtarenal abdominal aortic aneurysm; **EL** endoleak; **LRA** left renal artery; **RRA** right renal artery; **SMA** superior mesenteric artery; **TAAA4** type 4 thoracoabdominal aortic aneurysm.

### Technical details

Femoral and brachial/axillar cutdowns were used in all patients. A total of 8 target vessels were catheterized: two patients required single-vessel chimney and the remainder two-vessel chimney. Target vessels were two superior mesenteric artery and six renal arteries. Technical success rate was 100%. There were no major complications and average admission period was 15 days (range 6-24).

### Short and mid-term outcomes

The 30-day mortality was 0% without any major complications. Follow-up CTA at 30 days excluded any procedure-related complications or endoleaks, including gutter-related endoleaks. Sac regression was observed in all patients.

Follow-up time was 20.2 months (range 4.7-38) and 3/5 of patients have expired due to non-aortic related pathologies, on average 18 months after surgery (range 4.7-38), with a 1-year survival of 80%. Target vessel patency during the follow-up period is 87.5% (1 renal artery occluded at 23 months). The three deaths were attributed to complications related to medical comorbidities: pneumonia, COPD exacerbation and acute heart failure.

## DISCUSSION

Our “real-world” institutional experience with ChEVAR revealed favorable short-term mortality and mid-term target vessel patency during the 20-month follow-up period. The significant medium and long-term mortality, despite non-aortic related, is explained by the baseline characteristics of these patients, with severe comorbidities and high ASA score.

Since the first use of ChEVAR, case reports and short series have been published. However, in 2015, the multicentric PERICLES registry revealed results comparable to other endovascular options. This supported the use of ChEVAR

as an off-the-shelf alternative.<sup>[3]</sup> The favorable short and medium-term outcomes of the PERICLES registry were further analyzed in a long-term analysis which revealed a 5-year 66% survival and 92% chimney graft branch vessel patency.<sup>[3]</sup>

A 2022 systematic review included 1019 patients assessed mid-term outcomes of ChEVAR for JAAA.<sup>[5]</sup> The study found survival and target vessel patency at 3 years of 81.4% and 95.1%, respectively. It should be noted that a large proportion of these studies were performed in high-volume referral centers and may not reflect real-world results.

Recently evidence, has emerged to better clarify how this technique compares to open repair and f/bEVAR in JAAA. Zlatanovic et al<sup>[6]</sup> found that ChEVAR and f/bEVAR had higher rates of aortic-related reintervention and side branch occlusion/stenosis when compared to open repair. The direct comparison between f/bEVAR and ChEVAR did not found significant differences in outcomes. It is noteworthy that this network meta-analysis was based in poor-quality and heterogenous studies (observational and registries). Open repair was not considered in our cohort due to severe prohibitive medical comorbidities in four patients and previous abdominal surgery and infection in one patient.

The applicability for ChEVAR may pose a problem when planning the procedure in some patients,<sup>[7]</sup> for which f/bEVAR may be better suited. In the emergent setting, off-the-shelf f/bEVAR can be a solution for a significant portion of these patients. The required upper limb access for ChEVAR is an additional disadvantage opposed to f/bEVAR which can currently be performed with femoral access only. Type 1 endoleak related to gutters remain a major concern for ChEVAR - despite an acceptable low rate.<sup>[5]</sup> However, complete and adequate sealing is mandatory in ruptured JAAA.

In our cohort off-the-shelf f/bEVAR was not considered due to the unavailability of these devices in our center. Physician modified endografts (PMEG) techniques were excluded due to inexperience with such procedures. It should also be

considered that f/bEVAR and PMEG require higher levels of expertise than ChEVAR. Compared to PMEG and ChEVAR, the off-the-shelf f/bEVAR leads to more extensive aortic coverage and sacrifice of segmental arteries, especially for JAAA. [\[8\]](#)

As opposed to custom-made f/bEVAR, ChEVAR offers immediately available with standard off-the-shelf devices, lower cost and access profile. Furthermore, ChEVAR may surpass certain anatomical contraindications for f/bEVAR, especially in the emergent setting. These complex endovascular procedures require continued surveillance to detect failure requiring interventions.

The main limitations of this study concern its small sample, single-centre and retrospective nature. Although major technical details overlap, the procedures were not standardised, and variations occurred.

## CONCLUSION

Our experience shows high technical success and low short-term morbidity and mortality with the use of ChEVAR for acute aortic aneurysms. High mid-term mortality was observed due to non-aortic causes. Sac regression, low rates of target vessel occlusion and type 1a endoleaks reveal a favourable profile for AAA exclusion. The ChEVAR technique is a viable option in the emergent setting for patients unfit for open repair.

**Acknowledgements:** None

**Conflicts of interest:** None

**Funding:** None

## REFERENCES

1. Wanhainen A, Verzini F, Van Herzelee I, Allaire E, Bown M, Cohnert T, et al. Editor's Choice – European Society for Vascular Surgery (ESVS) 2019 Clinical Practice Guidelines on the Management of Abdominal Aorto-iliac Artery Aneurysms. *Eur J Vasc Endovasc* 2019;57:8–93.
2. Greenberg RK, Clair D, Srivastava S, Bhandari G, Turc A, Hampton J, et al. Should patients with challenging anatomy be offered endovascular aneurysm repair? *J Vasc Surg* 2003;38:990–6.
3. Donas KP, Lee JT, Lachat M. Collected World Experience About the Performance of the Snorkel/Chimney Endovascular Technique in the Treatment of Complex Aortic Pathologies: The PERICLES Registry. *J Vasc Surg* 2015;62:1677.
4. Taneva GT, Lee JT, Tran K, Dalman R, Torsello G, Fazzini S, et al. Long-term chimney/snorkel endovascular aortic aneurysm repair experience for complex abdominal aortic pathologies within the PERICLES registry. *J Vasc Surg* 2021;73:1942–9.
5. Prapassaro T, Teraa M, Chinsakchai K, Hazenberg CEVB, Hunnangkul S, Moll FL, et al. Mid-Term Outcomes of Chimney Endovascular Aortic Aneurysm Repair: A Systematic Review and Meta-analysis. *Ann Vasc Surg* 2022;79:359–71.
6. Zlatanovic P, Jovanovic A, Tripodi P, Davidovic L. Chimney vs. Fenestrated Endovascular vs. Open Repair for Juxta/Pararenal Abdominal Aortic Aneurysms: Systematic Review and Network Meta-Analysis of the Medium-Term Results. *J Clin Med* 2022;11:6779
7. Gallitto E, Faggioli G, Loggiacco A, Mascoli C, Spath P, Palermo S, et al. Anatomical feasibility of the current endovascular solutions for Juxtarenal aortic abdominal aneurysm repair. *Vascular* 2023;31:833–40
8. Spath P, Tsilimparis N, Furlan F, Hamwi T, Prendes CF, Stana J. Additional Aortic Coverage With Off The Shelf, Multibranched Endograft Compared With Custom-Made Devices For Endovascular Repair of Pararenal Abdominal Aortic Aneurysm. *Eur J Vasc Endovasc Surg* 2023;65:710–8.