

Autopsy image following aortic arch parallel grafting of a ruptured aortic aneurysm

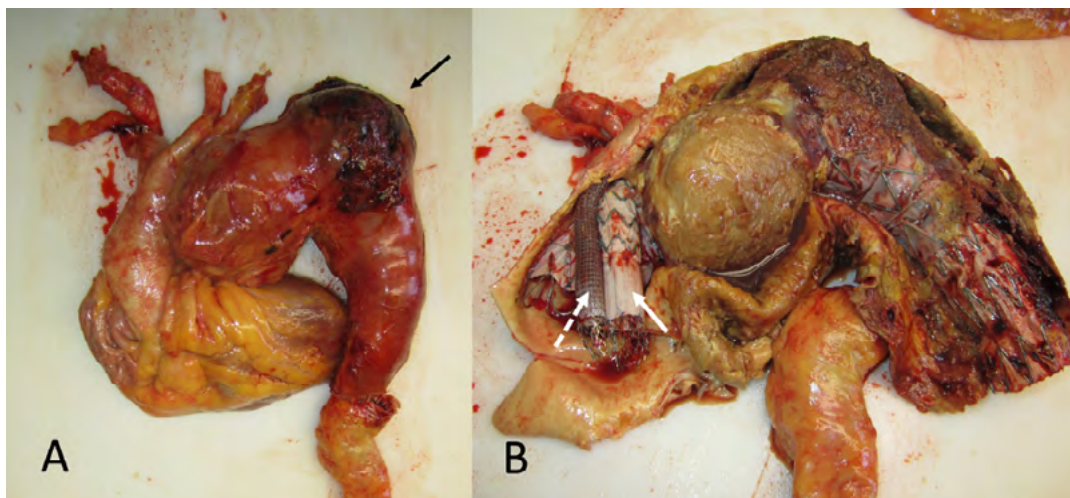
Ryan Gouveia e Melo ^{ID}, Ruy Fernandes e Fernandes ^{ID}, Luís Silvestre, Luís Mendes Pedro ^{ID}, José Fernandes e Fernandes ^{ID}

Department of Vascular Surgery, Centro Hospitalar Universitário Lisboa Norte; Faculdade de Medicina da Universidade de Lisboa; Centro Cardiovascular da Universidade de Lisboa (CCUL@RISE).

Submitted: February 4th, 2023; Accepted: February 6th 2023

An 85-year-old man was admitted with a ruptured thoracic aortic aneurysm involving the mid/distal arch (bovine aortic arch) and proximal descending thoracic aorta. An emergent endovascular repair was performed with zone 0 TEVAR using a COOK® Zenith Thoracic Alpha endograft and endo-debranching of the innominate artery (IA) and left carotid artery (LCA) using parallel (chimney) grafts through right axillary and LCA cutdown access. An iliac limb (COOK® ZSLE) for the IA and a Viabahn (GORE®) for the LCA were used and both chimneys were relined using a self-

expandable bare-metal stents. The left subclavian artery was covered and coiled. Although the rupture was sealed, the patient developed post-operative respiratory insufficiency, pneumonia and atelectasis related to the hemothorax. He died due to multiorgan failure at the 26th post-operative day. An autopsy was performed, where the aortic aneurysm with the ruptured hematoma is evident (A, arrow) and the position of the endograft, innominate artery chimney (B, arrow) and left carotid artery chimney (B, dotted arrow) can be seen in a ballerina position.



Corresponding Author:

Ryan Gouveia e Melo, MD | fryan@campus.ul.pt
Hospital de Santa Maria – Centro Hospitalar Universitário Lisboa Norte, EPE, Serviço de
Angiologia e Cirurgia Vascular. Avenida Professor Egas Moniz, 1649-028, Lisboa, Portugal.

Angiol Vasc Surg 2022;18(4):256
DOI: <https://doi.org/10.48750/acv.536>

