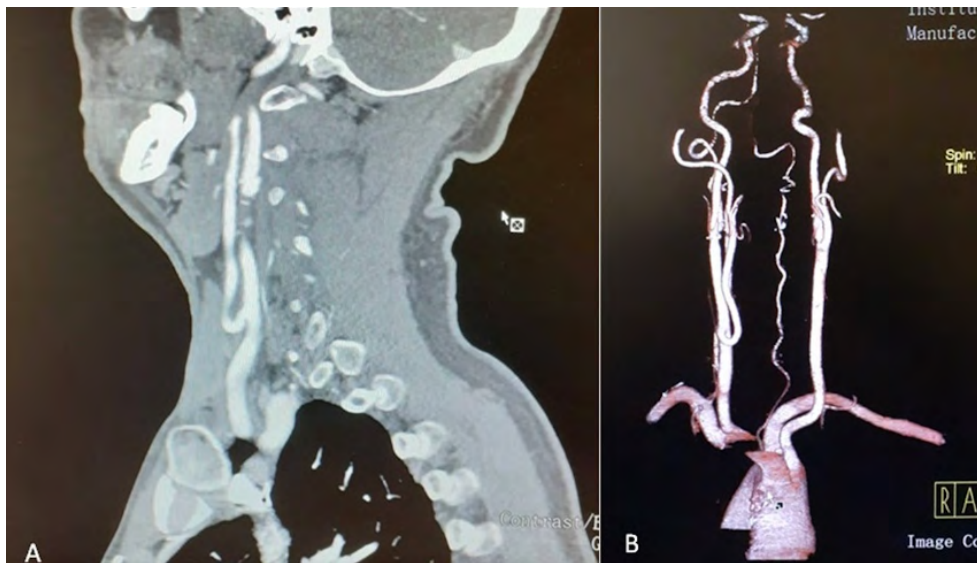


# Anatomical variation of the carotid bifurcation

Roberto Cunha , Pedro Sousa , Mafalda Correia , Isabel Vieira , Isabel Cássio, Nelson Oliveira , Emanuel Dias

Serviço de Angiologia e Cirurgia Vascular do Hospital Divino Espírito Santo, Ponta Delgada, Portugal

Submitted: December 26<sup>th</sup>, 2022; Reviewed: January 14<sup>th</sup>, 2023; Accepted: March 12<sup>th</sup>, 2023



The level of the carotid bifurcation may be variable but is usually situated between the upper horn of the thyroid cartilage and the 4th cervical vertebra. In the Klippel-Feil anomaly, it may be located at an intrathoracic level. Ethnic variations, with the carotid bifurcation being more cephalic in African-Americans and Asians compared to Caucasians have also been described. Individually, differences in carotid bifurcation also arise, with a higher level on the right side. A 61-year-old male patient proposed for kidney transplant

underwent Doppler ultrasound to exclude obstructive disease, followed by computed tomography angiography. An abnormally low, tortuous and asymmetrical right carotid bifurcation was identified associated with tortuosity of the external carotid emergence (A). A marked asymmetry, with a high left carotid bifurcation, was noted (B).

**Keywords:** Carotid Artery Bifurcation; Anatomic Variations

**Corresponding Author:**

Roberto Cunha | roberto.sb.cunha@azores.gov.pt  
Angiology and Vascular Surgery Department, Hospital do Divino Espírito Santo (HDES),  
Av. D. Manuel I, 9500-370, Ponta Delgada, São Miguel Island, Azores, Portugal

Angiol Vasc Surg 2023;19(1):50  
DOI: <https://doi.org/10.48750/acv.529>

