

Endovascular approach as first-line therapy for congenital arteriovenous malformations – a case series

Andreia Pinelo , Luís Loureiro , Paulo Almeida , Daniel Mendes , Carlos Veterano , João Castro ,
Henrique Rocha , Rui Almeida 

Department of Angiology and Vascular Surgery, Centro Hospitalar do Porto, Portugal

Received: June 12, 2022; Reviewed: July 17, 2022; Accepted: August 26, 2022

Presented at: 21st Annual Meeting of the Portuguese Society for Angiology and Vascular Surgery (SPACV)

ABSTRACT

INTRODUCTION: Congenital vascular malformations are entities with a broad spectrum of presentations and variable prognosis. They typically present at a young age and are historically associated with extensive resection surgeries and with high morbidity. This study aims to evaluate the results of arteriovenous malformations (AVMs) embolization as a first-line approach in lesions which are not suitable for surgical resection.

METHODS: A retrospective analysis of the clinical records of patients with infiltrative arteriovenous malformations who underwent embolization at our center between 2019 and 2021 was performed. The Schobinger Classification was applied to categorize the clinical stage. Angiographic findings were reported according to the Yakes classification. The decrease in the Schöbinger grade after treatment, the need for reintervention and the associated complications were the main outcomes. A descriptive statistical analysis was performed.

RESULTS: Nine patients undergoing embolization of infiltrative arteriovenous malformations were evaluated, accounting for a total of seventeen interventions. There was a preponderance of females (n=6; 66.7%) and the mean age of referral to the Vascular Surgery consultation and the first treatment was 16.8 (± 12.9) and 20.9 (± 14.5) years, respectively. All patients were in stage II (n=4; 44.4%) or III (n=5; 55.6%) of Schöbinger. The angiographic pattern of the AVMs was classified according to the Yakes Classification, which guided the approach. Yakes type IIa was found most frequently (n=6; 55.6%), followed by type IV (n=2; 22.2%) and type IIb (n=1; 1.1%). Patients underwent AVM embolization via transarterial, transvenous or direct nidus puncture with sclerosing agents, liquid embolizers, microparticles and microcoils, separately or in combination. The median number of interventions per patient was 1 (1 – 5) and Yakes type IV appears to be associated with a higher rate of reintervention. Reduction of the Schöbinger stage was achieved in 7 (77.8%) patients with clinical resolution in 3 (33.3%). Tissue necrosis was the only complication reported in this series (n=2; 11,8%).

CONCLUSION: The endovascular approach of arteriovenous malformations through nidus and/or afferent/efferent embolization requires a detailed angiographic characterization but seems to be an effective strategy with a low risk of complications. The Yakes classification, can be useful both in guiding the approach and in predicting the need for reintervention.

Keywords: Arteriovenous malformation; vascular anomalies; embolization; endovascular; Yakes Classification

Corresponding Author:

Andreia Pinelo | afbpinelo@gmail.com
Department of Angiology and Vascular Surgery, Centro Hospitalar do Porto
Largo do Prof. Abel Salazar, 4099-001, Porto, Portugal

Angiol Vasc Surg 2022;18(3):176-81

DOI: <https://doi.org/10.48750/acv.488>



INTRODUCTION

Congenital vascular malformations present a broad phenotypic spectrum, ranging from skin changes with exclusive capillary involvement to large arteriovenous communications potentially limb and life-threatening.^[1,2] Arteriovenous malformations (AVMs) are a rare subgroup, characterized by high-flow communication between the arterial and venous systems through an aberrant vascular nidus that has replaced the normal capillary bed.^[3-6] They typically present at a young age and with reported progression rates of up to 96%, especially during puberty.^[3,6,7] Uncertainties regarding the pathophysiology and natural history associated with the lesion's high complexity often culminate in poor therapeutic planning^[8,9] and AVMs are historically associated with extensive resection surgeries with high morbidity and recurrence, regardless of the approach.^[9,10] The different classifications, although not perfect, aim not only the categorization of the different vascular malformations but also allow a better understanding of their pathophysiology (Modified Hamburg Classification^[11] – Table 1.), clinical course (Schobinger Classification^[12] – Table 2.) and angioarchitecture (Yakes Classification^[12] – Table 3.). Thus, they can support the clinical decision in the absence of other specific guidelines. The evolution of the endovascular technique marked a turning point in the treatment of this pathology. Initially intended as an adjunct to conventional surgery, this approach has been gaining ground as a first-line therapy. This study aims to evaluate the results of embolization of arteriovenous malformations as a first-line approach in infiltrative lesions, unresectable by conventional surgery.^[12]

Table 1. Hamburg Classification

Congenital Vascular Malformations – Types	
Arterial defects	
Venous defects	
Arteriovenous shunting defects	
Combined vascular defects – hemolymphatic defects	
Capillary defects	
Congenital Vascular Malformations – Embryologic subtypes	
Extratranocular forms	
Infiltrating, diffuse	
Limited, localized	
Troncular forms	
Stenosis or obstruction	
Hypoplasia, aplasia, hyperplasia	
Membrane, congenital spur	
Dilation	
Localized (aneurysm)	
Diffuse (ectasia)	

Modified from the original classification based on the consensus reached at the international workshop in Hamburg, Germany, 1988

Table 2. Schöbinger Staging of Arteriovenous Malformations

I (quiescent)	Warm areas of pink-blue discoloration
II (expansion)	Mass associated with thrill and bruit
III (destruction)	Mass associated with pain, bleeding and ulceration
IV (decompensation)	High output cardiac decompensation

Table 3. Yakes Arteriovenous Malformation Classification

I	Direct AVF
IIa	Typical AVM nidus
IIb	AVM nidus with shunt into an aneurysmal vein
IIIa	Aneurysmal vein whereby the vein wall is the nidus with single outflow vein
IIIb	Aneurysmal vein whereby the vein wall is the nidus with multiple outflow veins
IV	Infiltrative form with constituted by numerous micro-fistulae

AVF – arteriovenous fistulae; **AVM** – arteriovenous malformation

METHODS

A retrospective analysis of the clinical records of patients with infiltrative arteriovenous malformations who underwent embolization at our tertiary institution between 2019 and 2021 was performed. Demographic, clinical, procedure-related and postoperative outcome data were extracted from medical records.

The Schöbinger Classification (Table 2) was applied to categorize the clinical stage. Angiographic findings were independently evaluated by 2 authors (Pinelo A. and Loureiro L.) and reported according to the Yakes classification (Table 3.). Differences were resolved through consensus. The decrease in the Schöbinger grade after treatment, the number of reinterventions and associated complications were the main outcomes.

Considering the small number of patients included in this series, only a descriptive statistical analysis was performed.

RESULTS

We evaluated nine patients who underwent embolization of extracranial infiltrative arteriovenous malformations, accounting for a total of seventeen interventions. The information is summarized in [Tables 4 and 5](#). There was a preponderance of female sex (n=6; 66.7%). The mean age of referral to the Vascular outpatient clinic and of the first treatment was 16.8 (\pm 12.9) and 20.9 (\pm 14.5) years, respectively, with a mean follow-up time of 18.9 \pm 11 months. All the patients who underwent treatment were in Schöbinger stage II (n=4; 44.4%) or III (n=5; 55.6%). The lower limb was predominantly affected (n=8, 88.9%). In all patients, the lesions were isolated events, and no other vascular malformations or associated pathologies were found. The initial diagnosis

was made through detection of vascular malformation with arteriovenous shunting by vascular ultrasound and later confirmed by magnetic resonance angiography (MRA). Digital subtraction angiography was performed during the procedure as a roadmap for the intervention. Angiographic

findings were classified according to the Yakes Classification (Table 3), which guided the chosen approach. The lesion nidus was the primary target of all interventions. Yakes type IIa anomaly was the most frequent (n=6; 66.7%), followed by type IV (n=2; 22.2%) and type IIb (n=1; 1.1%).

Table 4 - Demographic and clinical characteristics

Case	Sex	Referral age (y)	Age at treatment (y)	Location	Follow-up time (months)	YAKES classification
1	M	15	15	Inguinal	18	IIa
2	F	6	7	Suprascapular	9	IIa
3	F	5	8	Thigh	9	IIa
4	F	10	19	Buttock	9	IIa
5	M	20	22	Buttock	13	IIa
6	F	22	28	Foot	37	IV
7	F	27	40	Foot	34	IV
8	F	3	4	Leg	27	IIb
9	M	43	45	Thigh	14	IIa

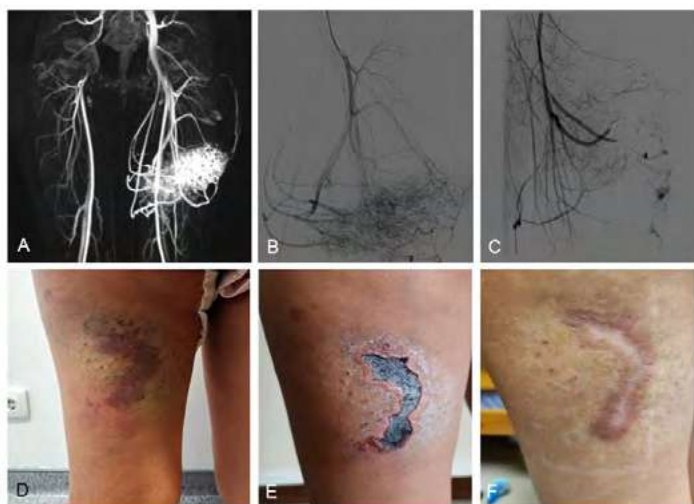
Table 5 - Procedure-related characteristics

Case	Access	Embolization material	Nr. of interventions	Schöbinger (pre-embolization)	Schöbinger (post-embolization)	Complications	Surgical Resection
1	TA	Polidocanol Onyx18®	2	III	II	∅	no
2	TA	Polidocanol Microcoils	1	II	∅	∅	no
3	TA	Polidocanol Microcoils PVA 500-710	1	II	∅	skin necrosis	no
4	TA	PVA 500-710	1	III	III	∅	no
5	TA	Polidocanol Onyx18®	2	III	I	∅	no
6	DNP TA TV	Polidocanol Microcoils Onyx34® PHIL®	5	III	III	∅	no
7	TA TV DNP	Polidocanol Onyx® Coil	4	III	I	tissue necrosis	yes
8	TV	Polidocanol	1	II	I	∅	yes
9	TA	Onyx18®	1	II	∅	∅	no

DNP – direct nidus puncture; **TA** – transarterial; **TV** – transvenous.

In patients with type IIa AVM (n=6) the nidus was embolized via transarterial approach with polidocanol (n=2), polidocanol + microcoils (n=1), polidocanol + microcoils + PVA 500-710microns (n=1), PVA 500-710microns (n=1) and Onyx18® (n=1) (Figure 1). The two patients treated with polidocanol alone required a second embolization, also performed via transarterial with Onyx18® 8 and 9 months after the first procedure. A reduction in Schöbinger's stage was achieved in 5 (83.3%) of the 6 patients in this group, with complete clinical resolution in 3 (50%).

Figure 1. Yakes type IIa arteriovenous malformation (AVM) of the thigh.



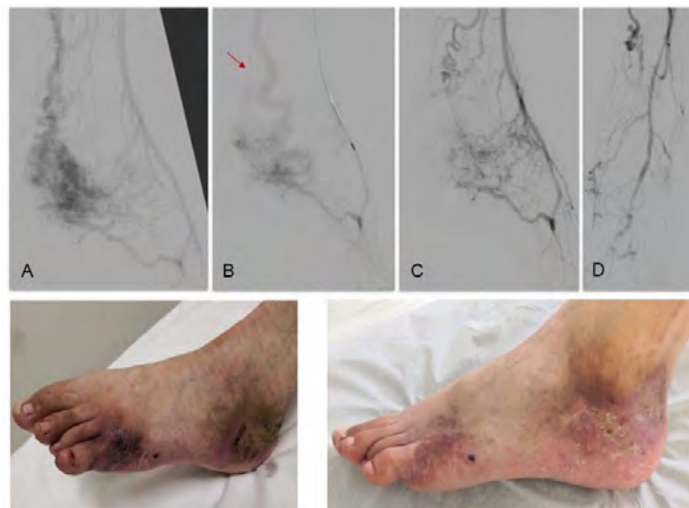A) magnetic resonance angiography (MRA) showing infiltrative AVM with afferent branches from the deep femoral artery; **B)** pre-treatment angiography; **C)** final result after nidus embolization with polidocanol (3%) and PVA 500-710microns and afferent obliteration with Concerto® microcoils (2x40(x2); 2x60; 2x80; 3x40(x2); 3x80); **D)** pre-treatment macroscopic findings; **E)** post-intervention necrosis of the overlying skin; **F)** complete healing by the 3rd month after embolization

Type IIb AVM (n=1) was embolized with polidocanol foam via transvenous approach. A reduction of volume and Schöbinger's stage from II to I was achieved. Surgical excision of the residual lesion was performed 1.5 months after embolization, without recurrence at two-year follow-up.

Type IV AVMs (n=2), both located in the foot, were the most complex lesions and had the highest number of interventions. In the first case, it was initially attempted polidocanol sclerosis through direct *nidus* puncture. Due to the absence of involution, the procedure was repeated four times with transarterial and transvenous embolization with polidocanol and PHIL®; an additional obliteration of the afference was carried out by placing a microcoil filled with Onyx34® in the posterior tibial artery and of the efference through anterior tibial vein sclerosis with polidocanol (Figure 2). It was achieved a clinical regression of the AVM with the favorable healing of ulcerated areas 30 days after the last procedure. In the second patient, four procedures were required with polidocanol and Onyx18® embolization via transarterial, transvenous and direct *nidus* puncture (Figure 3). There was involution of the lesion with delimitation of extremity necrosis zone requiring

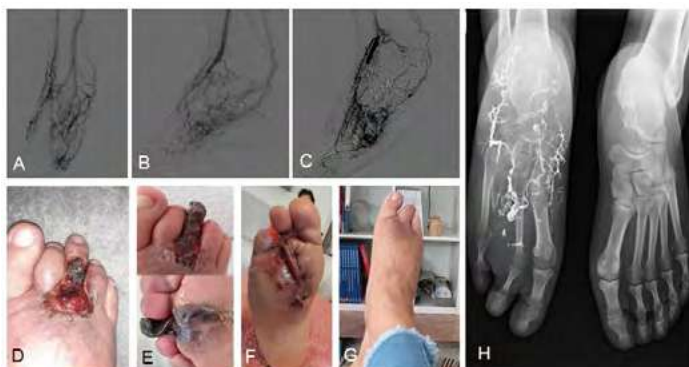toe amputation. During a two-year follow-up after the last intervention, it persists a residual cutaneous malformation being treated with 940nm vascular laser therapy intermittent sessions.

Figure 2. Yakes type IV arteriovenous malformation (AVM) of the foot



A) pre-treatment angiography, inflow through branches from the posterior tibial, peroneal and pedal arteries; **B)** angiography after transarterial *nidus* embolization with polidocanol (3%) foam and posterior tibial artery obliteration with Concerto® 4x100 microcoil (arrow) and Onyx34®; *nidus* access was not compromised given the additional afference by peroneal and pedal arteries' branches; **C and D)** angiographic result after transvenous sclerosis with polidocanol (3%) foam of the efferent anterior tibial vein (C) and transarterial nidus embolization nidus with PHIL® 30% via peroneal artery (D), performed during the same procedure; **E)** pre-treatment clinical findings with painful foot ulceration; **F)** healing ulcerations after last treatment.

Figure 3. Yakes type IV arteriovenous malformation (AVM) of the foot



A) pre-treatment angiography; inflow through anterior and posterior tibial arteries branches; **B)** angiography after transarterial coil obliteration and Onyx18® embolization of plantar inflow branches, through posterior tibial artery and great saphenous vein sclerosis with polidocanol foam (3%); **C)** angiography after direct *nidus* Onyx18® injection followed by embolization of posterior tibial artery plantar branches and distal pedal artery obliteration, both with Onyx18®; **D)** clinical presentation with toe painful ulcer; **E)** toe necrosis after the last embolization treatment; **F)** atypical transmetatarsic toe amputation and residual AVM excision; **G)** Completely healed and functional stump with resolution of pain complaints; **H)** post-amputation X-Ray

Overall, the median number of interventions per patient was 1 (ranging from 1 to 5) and Yakes type IV appears to be associated with a higher rate of reintervention. Reduction of the Schöbinger stage was achieved in seven out of the nine patients (77.8%) patients, with clinical resolution in three (33.3%). We report a 11.8% (n=2) complication rate, both involving tissue necrosis. One patient with Yakes type IIa AVM treated with transarterial nidus embolization (Figure 1-C) complicated superficial necrosis of the overlying skin (Figure 1-E) which detached and completely healed (Figure 1-F). The other patient, presenting with a type IV Yakes AVM, developed complete toe necrosis (Figure 3-E) after transarterial and direct nidus embolization and pedal artery obliteration (Figure 3-C). We performed an atypical transmetatarsic 3rd and 4th toes amputation with excision of the residual nidus (Figure 3-F) which completely healed, preserving a functional foot. There were no other complications reported associated to the procedures.

DISCUSSION

Arteriovenous malformations manifest at a young age with an unpredictable and potentially life-threatening course. There are no specific guidelines for treatment and, while some centers recommend intervention in stages III and IV of Schöbinger,^[13] others adopt an earlier approach due to the high risk of progression^[1]. There is little consensus on the best approach and it is difficult to establish a comprehensive strategy given the pathology's clinical variability and complex stratification. Conventional surgery with complete resection is still the most effective treatment in small and localized lesions^[12] but it becomes less suitable for extensive and infiltrative lesions.^[13] The evolution of endovascular techniques has allowed new therapeutic perspectives, both as a bridge to conventional surgery and also as a primary therapy for lesions that cannot be surgically resected. The results of AVM embolization described in the literature are divergent and difficult to interpret given the absence of a clear stratification and standardized criteria. Also, most studies include only AVMs of the head and neck, presumably due to the complexity of surgical resection in this location, turning the use of endovascular techniques more desirable. The success rate of embolization varies between 18 and 92%,^[3,13-21] reflecting the different complexity of the treated lesions as well as different definitions of technical and clinical success and variations in technique inherent to the variations between operators and centers. In our series we report a clinical success rate, defined as a decrease in the Schöbinger stage, of 77.8%. The number of interventions per patient was significantly higher in Yakes type IV AVMs, which is in line with the results reported by Griauzde J. et al.^[22] Several medications have been tried for the treatment of infiltrative AVMs, targeting different angiogenesis and vascular remodeling pathways, which seem to play a crucial role on their pathophysiology.^[23,24] Six major pharmaceutical classes have been used as off-label therapy based on this rationale: **1)** Thalidomide, **2)** mTOR acting drugs (Rapamycin/Sirolimus and derivatives), **3)** Matrix-Metallo-Proteinase-Inhibitors (Doxycycline, Marimastat and others), **4)** Selective VEGF pathway inhibitors (Bevacizumab and others), **5)** β -adrenergic

inhibitors (Propranolol) and **6)** Interferon.^{4,23-25} More recently, the MEK inhibitor (trametinib) has also been successfully used, based on the recent association between AVMs and MAP2K1 mutations.^[26] All of these therapies have variable results and none of them has yet been approved as current therapy. However, they appear, in our perspective, as potential adjuvants to the endovascular therapy and may reduce the progression and therefore the number of interventions in high-risk patients, such as the Yakes type IV AVMs.

Tissue necrosis was reported in two patients, requiring toe amputation in one of them. Though, the previous embolization procedures culminated with the involution of the lesion and allowed us to perform a minor amputation to control the patient's symptoms and significantly improved her quality of life.

Although the reduced number of patients included do not allow the extrapolation of large-scale conclusions, the results obtained were satisfactory both in terms of efficacy and safety.

CONCLUSION

Endovascular treatment of arteriovenous malformations through nidus and/or afferent/efferent embolization requires a detailed angiographic characterization. Still, it seems to be an effective therapeutic strategy with a low risk of complications. An approach guided by the understanding of the angioarchitecture appears to optimize the results of endovascular treatment and the Yakes Classification seems to be not only an important tool for the approach's choice but also a predictor of the clinical course and need for reintervention. However, the natural history of this pathology remains inadequately understood, curative perspectives still offer marginal results and the intervention should now be focused on preventing the destructive progression of these lesions, always requiring long-term follow-up.

Acknowledgements None

Conflicts of interest None

Funding None

REFERENCES

1. Lee BB, Do YS, Yakes W, Kim DI, Mattassi R, Hyon WS. Management of arteriovenous malformations: a multidisciplinary approach. *J Vasc Surg.* 2004;39:590-600.
2. Lee BB. New approaches to the treatment of congenital vascular malformations (CVMs)--a single centre experience. *Eur J Vasc Endovasc Surg.* 2005;30:184-97.
3. Zou Y, Qiao C, Lin X, Jin Y, Hua C, Yang X, et al. Clinical Course of Extracranial Arteriovenous Malformations. *J Craniofac Surg.* 2020;31:372-8.
4. Chastanet S, Maruani A, Laure B, Herbreteau D, Joly A. Effect of Beta-blockers on Extracranial Arteriovenous Malformations. *Acta Derm Venereol.* 2022;102:adv00680.
5. Kohout MP, Hansen M, Pribaz JJ, Mulliken JB. Arteriovenous malformations of the head and neck: natural history and management. *Plast Reconstr Surg.* 1998;102:643-54.
6. Schmidt VF, Masthoff M, Czihal M, Cucuruz B, Häberle B, Brill R, et al. Imaging of peripheral vascular malformations - current concepts and future perspectives. *Mol Cell Pediatr.* 2021;8:19.
7. Liu AS, Mulliken JB, Zurakowski D, Fishman SJ, Greene AK. Extracranial arteriovenous malformations: natural progression and recurrence after treatment. *Plast Reconstr Surg.* 2010;125:1185-94.

- 8.** Frey S, Haine A, Kammer R, von Tengg-Koblighk H, Obrist D, Baumgartner I. Hemodynamic Characterization of Peripheral Arterio-venous Malformations. *Ann Biomed Eng.* 2017;45:1449-61.
- 9.** Richter GT, Suen JY. Clinical course of arteriovenous malformations of the head and neck: a case series. *Otolaryngology--head and neck surgery: Otolaryngol Head Neck Surg.* 2010;142:184-90.
- 10.** Hawkins CM, Chewning RH. Diagnosis and Management of Extracranial Vascular Malformations in Children: Arteriovenous Malformations, Venous Malformations, and Lymphatic Malformations. *Semin Roentgenol.* 2019;54:337-48.
- 11.** Villavicencio B-BlLeJL. Congenital Vascular Malformations : General Considerations. *Rutherford's Vascular Surgery and Endovascular Therapy, . Chapter 171.* p. 2236-50.e4.
- 12.** Daniel M. O'Mara CRW. Congenital Vascular Malformations: Endovascular Management. *Rutherford's Vascular Surgery and Endovascular Therapy.* p. 2259-72.e2.
- 13.** Soulez G, Gilbert Md Frcpc P, Giroux Md Frcpc MF, Racicot Md Frcpc JN, Dubois J. Interventional Management of Arteriovenous Malformations. *Tech Vasc Interv Radiol.* 2019;22:100633.
- 14.** Dmytriw AA, Ter Brugge KG, Krings T, Agid R. Endovascular treatment of head and neck arteriovenous malformations. *Neuroradiology.* 2014;56(3):227-36.
- 15.** Kim B, Kim K, Jeon P, Kim S, Kim H, Byun H, et al. Long-term results of ethanol sclerotherapy with or without adjunctive surgery for head and neck arteriovenous malformations. *Neuroradiology.* 2015;57:377-86
- 16.** Pekkola J, Lappalainen K, Vuola P, Klockars T, Salminen P, Pitkäranta A. Head and neck arteriovenous malformations: results of ethanol sclerotherapy. *Am J Neuroradiol.* 2013;34:198-204.
- 17.** Vogelzang RL, Atassi R, Vouche M, Resnick S, Salem R. Ethanol embolotherapy of vascular malformations: clinical outcomes at a single center. *J Vasc Interv Radiol.* 2014;25:206-13; quiz 14.
- 18.** Zheng LZ, Fan XD, Zheng JW, Su LX. Ethanol embolization of auricular arteriovenous malformations: preliminary results of 17 cases. *Am J Neuroradiol.* 2009;30:1679-84.
- 19.** Jin Y, Lin X, Chen H, Hu X, Fan X, Li W, et al. Auricular arteriovenous malformations: potential success of superselective ethanol embolotherapy. *J Vasc Interv Radiol.* 2009;20:736-43.
- 20.** Qu ZY, Yang B, Yang FY, Liao ZY. Efficiency and safety of ethanol sclerotherapy for labial arteriovenous malformations. *J Vasc Surg Venous Lymphat Disord.* 2022;10:713-20.e1.
- 21.** Bouwman FCM, Botden S, Verhoeven BH, Schultze Kool LJ, van der Vleuten CJM, de Blaauw I, et al. Treatment Outcomes of Embolization for Peripheral Arteriovenous Malformations. *J Vasc Interv Radiol.* 2020;31:1801-9.
- 22.** Griauzde J, Wilseck ZM, Chaudhary N, Pandey AS, Vercler CJ, Kasten SJ, et al. Endovascular Treatment of Arteriovenous Malformations of the Head and Neck: Focus on the Yakes Classification and Outcomes. *J Vasc Interv Radiol.* 2020;31:1810-6.
- 23.** Rosenberg TL, Suen JY, Richter GT. Arteriovenous Malformations of the Head and Neck. *Otolaryngol Clin of North Am.* 2018;51:185-95.
- 24.** Colletti G, Dalmonte P, Moneghini L, Ferrari D, Allevi F. Adjuvant role of anti-angiogenic drugs in the management of head and neck arteriovenous malformations. *Med Hypotheses.* 2015;85:298-302.
- 25.** Blatt J, McLean TW, Castellino SM, Burkhart CN. A review of contemporary options for medical management of hemangiomas, other vascular tumors, and vascular malformations. *Pharmacol Ther.* 2013;139:327-33.
- 26.** Lekwuttikarn R, Lim YH, Admani S, Choate KA, Teng JMC. Genotype-Guided Medical Treatment of an Arteriovenous Malformation in a Child. *JAMA Dermatol.* 2019;155:256-7.