

ANEURISMA ROTO DA AORTA ABDOMINAL COM ANATOMIA EM PIRÂMIDE

“EVEREST-LIKE” RUPTURE ABDOMINAL AORTIC ANEURISM

Daniel Mendes*¹; Joana Martins¹; Rui Machado^{1,2}; Inês Antunes¹; Carlos Veiga¹; Carlos Veterano¹; Henrique Rocha¹; João Castro¹; Andreia Pinelo¹; Rui Almeida^{1,2}

1. Serviço de Angiologia e Cirurgia Vascular, Centro Hospitalar Universitário do Porto

2. Instituto de Ciências Biomédicas Abel Salazar - Universidade do Porto

Recebido a 10 de novembro de 2020

Aceite a 29 de dezembro de 2020

Palavras-chave

Aneurisma da aorta abdominal; Cirurgia vascular; Cirurgia aberta

Keywords

Abdominal Aortic Aneurysm; Vascular Surgery; Open surgery

CLINICAL CASE

80-year-old woman, in need of some assistance in daily activities with a history of arterial hypertension, psoriasis and incipient demential syndrome, was admitted to the emergency department of a peripheral hospital due to severe abdominal pain and shortness of breath. She was hemodynamically stable with a globally painful abdomen and palpable epigastric mass. From the analytical study, she presented with anemia (hemoglobin of 8.3g/dL) and acute kidney injury. Due to the history of Abdominal Aortic Aneurysm (AAA), thoracoabdominopelvic computed tomography (CT) angiography was performed (fig. 1), which revealed a moderate increase in the caliber of the thoracic aorta in its different segments. The ascending aorta was a transversal diameter of 45mm and the descending aorta of 35mm. In the abdomen, a large aortic aneurysm was evident, with a conic morphology and a maximum anteroposterior and transverse diameter of 102x89mm. The anterior border of the aneurysm protruded through the left rectus abdominis muscle, with a small rupture contained in its posterolateral surface.

She underwent urgent treatment, which, due to the anatomy made endovascular intervention impossible. An open aorto-aortic bypass was performed using an 18mm woven polyester prosthesis (fig 2). The procedure complicated intraoperatively with bilateral iliofemoral occlusion requiring bilateral transfemoral thromboembolectomy. The estimated losses during the procedure were around 1000cc. In total, the patient received 4 red blood cell transfusions. In the postoperative period, the patient developed a refractory shock non-responding to any measures and eventually died 4 hours after the procedure.

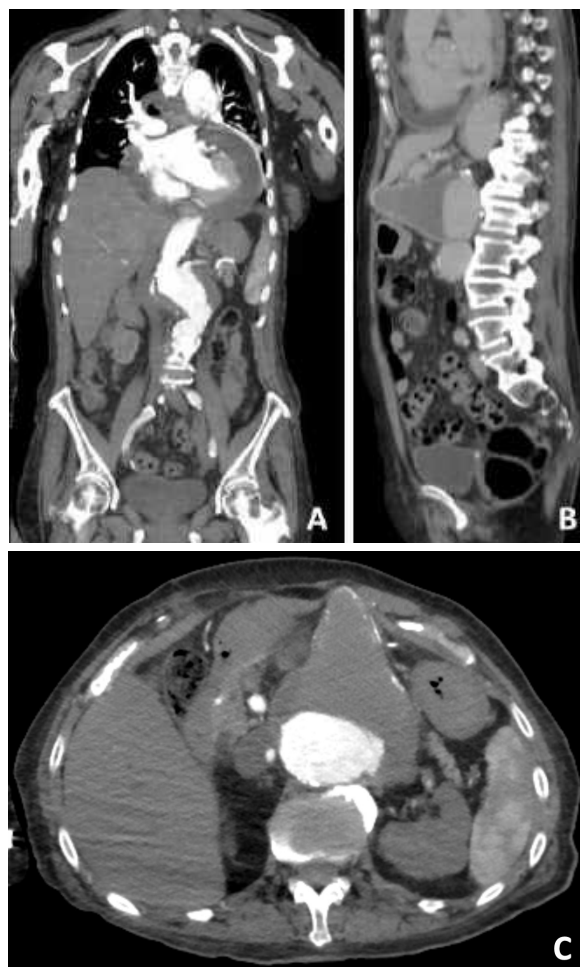


Figure 1 Computed angiogram (CTA) showing a large abdominal aortic aneurysm with a conical shape and contained rupture (A - coronal, B - sagittal and C - axial planes).

*Autor para correspondência.

Correio eletrónico: daniel5.mds@gmail.com (D. Mendes).

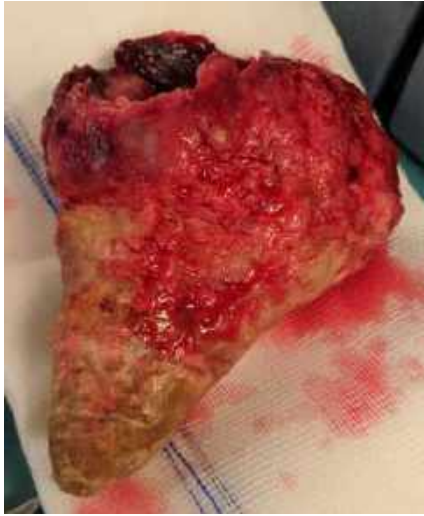

Figure 2 Large thrombus removed from the inside of the aneurysm with a conical shape

DISCUSSION

Abdominal aortic aneurysm is a relatively common pathology and if left untreated, it has a high mortality. It is more frequent in men with a frequency of 4-7% after the age of 50. In women, although rarer (prevalence of 1% after 50 years of age), it presents a higher mortality rate and more often presents with rupture.⁽¹⁾ In case of a rupture, mortality is approximately 81%.⁽²⁾ Prior diagnosis and treatment when indicated is essential in order to reduce mortality. In older patients, the prognosis is even poorer. Here we present a case of treatment of ruptured abdominal aortic aneurysm of an elderly patient with an uncommon morphology.

REFERENCES

1. Mussa FF. Screening for abdominal aortic aneurysm. *J Vasc Surg.* 2015;62(3):774-778.
2. Reimerink JJ, van der Laan MJ, Koelemay MJ, Balm R, Legemate DA. Systematic review and meta-analysis of population-based mortality from ruptured abdominal aortic aneurysm. *Br J Surg.* 2013;100(11):1405-1413.

